



PATIENT

Pepper Byrnes

SPECIES

Feline

BREED

Russian Blue

SEX

Male Neutered

AGE

8.10 years

WEIGHT

9.4lbs

INTERPRETED BY

Maggie Machen Lamy,
DVM, DACVIM
(Cardiology)

IMAGING PERFORMED BY

Melinda Persson, DVM

HOSPITAL NAME

At Home Veterinary

REFERRING VET

Dr. Persson

INVOICE

46822

DATE

2/12/26

PRESENTING CLINICAL SIGNS

History: Recheck echo. Grade 2/6 heart murmur. Normal BNP.

-Pertinent previous echo findings (8/2024): slightly enlarged anterior papillary muscle and impaired left ventricular relaxation. Benign murmur due to turbulent flow within the left and right ventricular outflow tracts.

ECHOCARDIOGRAM FINDINGS

2D, m-mode, color flow and doppler imaging is available. The left ventricular wall is normal in dimension. There is a mildly hyperechoic endocardium consistent with age-related fibrosis. Mild remodeling. The papillary muscles are hyperechoic yet normal in size. The left atrium is normal in size. The right atrium is normal in size. The right ventricle appears normal. The mitral valve is normal in structure and mobility. No MR or SAM identified. The tricuspid valve appears normal in structure and mobility. Trace TR. Normal velocity. Blood flow through both the LVOT and RVOT are normal in velocity. Trace AI. No PI. No effusions. No obvious cardiac tumors.

CARDIAC CHART

FELINE CARDIAC PARAMETERS	BODY WEIGHT (kg)	HR (BPM)	IVSd (cm) (Moise, Pipers)	LVIDd (cm) (Moise, Pipers)	LVWd (cm) (Moise, Pipers)	FS (%)	EF (%)
NORMAL PARAMETER	-----	150-240	0.35-0.55	<2 (mean 1.5)	3.5-0.55	35-67	80-100
PATIENT	4.3	NM	0.47	1.2	0.45	47	90
FELINE CARDIAC PARAMETERS	LA/AO (Boon)	LA/AO HEART BASE (Swe) (Abbott)	LA 2D short axis Base view (cm) (Abbott)		LVOT VEL (m/s)	RVOT VEL (m/s)	E max (m/s)
NORMAL	<1.5	<1.3	<1.2		<1.6	<1.3	<0.9
PATIENT	NM	1.3	1.1		0.8	1.0	NM

**Note: All measurements based upon multi-modal images and methods. An average value is reported.*
 Adapted from June Boon, Veterinary Echocardiography, 1998
 Abbott J & MacLean H JVIM 2006;20: 111-119, Moise et al. Am J Vet Res 47:1476, 1986. Pipers et al. Am J Vet Res 40:882, 1979.

INTERPRETATION OF THE FINDINGS & FURTHER RECOMMENDATIONS

Overtly normal cardiac structure and function. Mild fibrosis of the left ventricular wall is noted, which is likely a normal age-related variant. No significant valve leaks are noted, and flow through the great vessels is normal in velocity. No definitive cause for the murmur is identified in this study, making it likely physiologic in origin (i.e. secondary to tachycardia, volume changes, etc.). Trace aortic insufficiency is noted, and a baseline BP is recommended. No additional issues are seen.

These findings in addition to a normal BNP likely suggest diastolic dysfunction and papillary changes were/are a normal age-related variant.



PATIENT

Pepper Byrnes

SPECIES

Feline

BREED

Russian Blue

SEX

Male Neutered

AGE

8.10 years

WEIGHT

9.4lbs

INTERPRETED BY

Maggie Machen Lamy,
DVM, DACVIM
(Cardiology)

IMAGING PERFORMED BY

Melinda Persson, DVM

HOSPITAL NAME

At Home Veterinary

REFERRING VET

Dr. Persson

INVOICE

46822

DATE

2/12/26

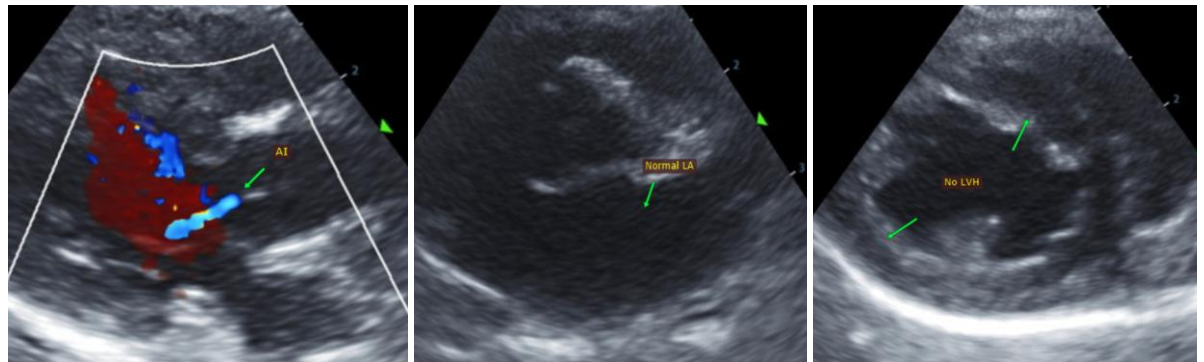
Given these findings and a normal LA dimension, no medications are indicated. Prognosis is open.

No cardiac contraindication for general anesthesia. Risk for complication with steroid or fluid use typically follows LA dilation, which in this case is low. That said, any cat can experience acute intolerance and monitoring for this phenomenon is always advised (a change in RR/RE, particularly during the initiation phase).

Monitor at home for signs of cardiac compromise, including respiratory changes and/or signs of a blood clot event (paralysis, neurologic changes).

Recommend recheck echocardiogram in 1 year to assess for any progressive issues or development of disease the pre-existing murmur may mask.

IMAGES



The information and recommendations provided are based on the images presented by the referring veterinarian. No evaluation can be communicated regarding pathology that was not visible in the image/video clips provided.

Thank you for this referral. This report was generated using transcription software, and minor dictation errors may be present. If the clinical or image interpretation does not parallel your findings or if I can be of any further assistance, please contact me.

Maggie Machen Lamy, DVM
Diplomate of the American College of Veterinary Internal Medicine (Cardiology)
info@sonopath.com